

Anterior Tooth Movement and Stability in Class I Crowding Patients Treated with Preadjusted Appliances

Hidefumi ITO, Kazuki OUE, Tatsuo RYU and Toshihiko HIMURO

The purpose of this study was to determine the movement of maxillary and mandibular anterior teeth before and after treatment of Class I crowding using preadjusted appliances (0.022" slot).

Thirty-six patients (17.70 ± 7.80 years) with Class I crowding who attained favorable occlusion after treatment were divided into the nonextraction and the extraction groups. Lateral cephalometric radiographs were analyzed before treatment, after treatment, and at retention, and cast models were analyzed before treatment.

In the extraction group, maxillary and mandibular incisors moved posteriorly, accompanied by lingual tipping, whereas mandibular central incisors demonstrated appropriate tooth axes, and condylar incisal angle approximated 90° . In the nonextraction group, maxillary central incisors moved anteriorly without changing torque, whereas condylar incisal angle decreased due to labial proclination of mandibular incisors. The means width of all the teeth from the incisor to the second molar, the arch-length discrepancy, and the irregularity index were significantly larger in the extraction group.

Class I crowding treatment with preadjusted appliances demonstrated favorable occlusion at retention in both groups, although there were intergroup differences in the movement of maxillary and mandibular central incisors. Thus, different treatment strategies should be applied from case to case : extraction treatment is effective to increase the torque of the maxillary central incisor's bracket prescription, whereas stripping of the mandibular teeth is effective in nonextraction treatment.

Key words : class I crowding, bracket prescription, anterior guidance, condylar incisal angle, preadjusted appliance

INTRODUCTION

Built-in prescriptions of preadjusted appliances determine the positions of maxillary and mandibular teeth and affect anterior guidance, which is important for aesthetics¹⁾ after orthodontic treatment, and shearing²⁻⁵⁾ by move-

ments caused by contact *between* these teeth. Thus, prescriptions play important roles in occlusion after orthodontic treatment.

In treatments using preadjusted appliances, alignment movement of anterior teeth varies widely with degree of malocclusion, treatment procedures, treatment mechanics, and extrac-

受付：平成25年6月28日，受理：平成25年7月16日
奥羽大学歯学部成長発育歯学講座歯科矯正学分野
(指導：福井和徳教授)

Division of Orthodontics and Dentofacial Orthopedics,
Department of Oral Growth and Development, Ohu
University School of Dentistry
(Director : Prof. Kazunori FUKUI)

tion/nonextraction status. Miyake *et al.*⁶⁾ revealed that extraction treatment of Class I crowding using preadjusted appliances leads to distal movement of anterior teeth and acumination of the maxillary dental arch, whereas non-extraction treatment causes maxillary and mandibular anterior teeth to move anteriorly. Under similar conditions, Cho *et al.*⁷⁾ reported that maxillary anterior teeth inclined lingually while also extruding and moving posteriorly and laterally.

We divided patients into two groups : extraction or nonextraction treatment for Class I crowding using preadjusted appliances. We compared the groups to assess movement of maxillary and mandibular anterior teeth during the retention period.

MATERIALS AND METHODS

1. Subjects and materials

This study included 36 patients with Angle Class I malocclusion who were treated according to a protocol with preadjusted appliances (.022×.028 inch slot, MBT set-up : U1, +17° ; L1, -6°)⁸⁾, could be followed throughout the retention period, and achieved good occlusion. We selected 24 patients (3 boys, 21 girls) with mean age of 17.30 ± 7.10 years in the extraction group, and 12 patients (4 boys, 8 girls) with mean age of 18.40 ± 9.40 years in the nonextraction group. There was no significant intergroup age difference.

Subjects had to meet the following criteria :

- (1) Skeletal Class I with Angle Class I malocclusion.
- (2) Absence of abnormalities in tooth crown morphology.
- (3) Absence of restoration and attrition that would affect measurements.
- (4) Absence of temporomandibular joint abnormalities.
- (5) No history of lateral expansion or distal

movement (treatment) of molars.

(6) No history of stripping.

(7) Use of a removable retainer.

(8) Retention period of 1 year or longer.

Study materials were lateral X-ray cephalograms taken before treatment (T1), after treatment (T2), and after retention (1 year after starting the retention period : T3), as well as dental-cast models taken before treatment. Active treatment period was 3.30 ± 1.30 years ; retention period was 1.10 ± 1.10 years.

Wraparound retainers were used for maxilla at retention. Hawley-type retainers were used for mandible. These devices were used all day for 3 months after removal of preadjusted appliances. Subsequently, patients were instructed to use retainers for as many hours as possible daily for at least 1 year.

2. Analysis

1) Cephalometric Analysis

Lateral cephalograms were acquired at T1, T2, and T3. The following angular and linear measurements were obtained : U1-FH plane, L1-mandibular plane, U1-APo plane, L1-APo plane, overbite, overjet, SNA, SNB, facial angle, and mandibular plane angle (Figure 1), as well as anterior guidance and condylar incisal angles (Figure 2).

2) Cast Model Analysis

Cast models of 21 patients (3 boys and 18 girls) from the extraction group and 10 patients (3 boys and 7 girls) from the nonextraction group were obtained at T1. Mesiodistal coronal width from central incisor to second molar in the maxilla and mandible was measured thrice using digital Vernier calipers. In addition, irregularity index⁹⁾, anterior Bolton ratio⁹⁾, and overall Bolton ratio were calculated.

3) Statistical analysis

For intragroup comparison of parameters, one-way repeated-measures analysis of variance (ANOVA) was performed, followed by Dun-

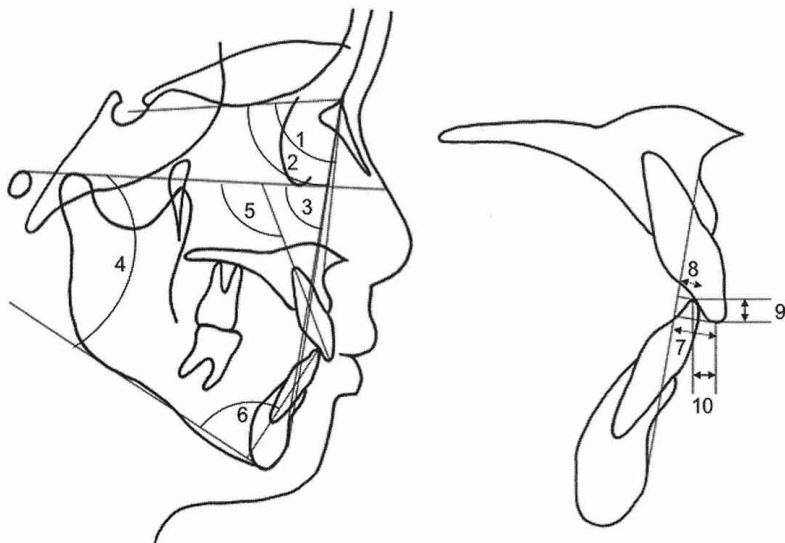


Figure 1. Lateral cephalometric measurements.

- (1) SNA (°), (2) SNB (°), (3) Facial angle (°), (4) Mandibular plane angle (°),
- (5) U1-FH plane (°), (6) L1-mandibular plane (°), (7) U1-APo plane (mm),
- (8) L1-APo plane (mm), (9) Overbite (mm), (10) Overjet (mm).

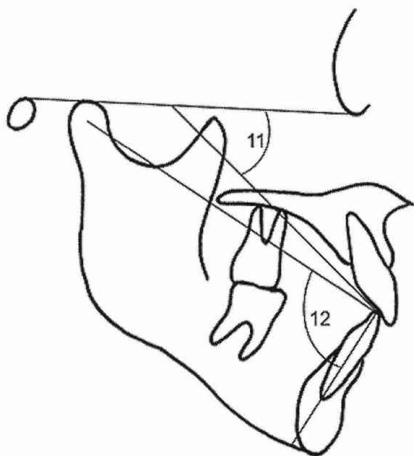


Figure 2. Measurement of anterior guidance and condylar incisal angles.

- (11) U1-L1 to FH plane (°).
- (12) Condylar incisal angle (°).

nett's multiple comparison. Unpaired t-tests were performed for intergroup comparisons at T1, T2, and T3, and for intergroup comparisons of coronal width, irregularity index, and Bolton analysis. SPSS 17.0J (SPSS Inc., Tokyo, Japan) was used for statistical analyses.

RESULTS

1. Cephalometric Analysis

There were no significant intergroup or intra-group differences in any skeletal or dental parameter (Table 1).

Regarding maxillary central incisors, in the extraction group, mean U1-FH plane value decreased significantly, from $116.19 \pm 5.27^\circ$ at T1 to $113.78 \pm 7.89^\circ$ at T2 (-2.40° , $P < .01$) and $111.68 \pm 7.17^\circ$ at T3 (-4.51° , $P < .01$). In the non-extraction group, no significant difference in this value was observed *between* time points. Mean U1-FH plane values at T2 and T3 were significantly smaller in the extraction group (T2 : $116.98 \pm 5.91^\circ$; T3 : $116.74 \pm 5.82^\circ$) (both $P < .05$).

Mean U1-APO value in the extraction group decreased significantly, from 9.36 ± 2.47 mm at T1 to 7.65 ± 2.23 mm at T2 (-1.71 mm, $P < .01$) and 7.44 ± 2.00 mm at T3 (-1.92 mm, $P < .01$). On the other hand, in the nonextraction group, mean U1-APo plane value increased signifi-

Table 1. Comparison of cephalometric measurements between the 2 groups.

Measurements		T1			T2			T3			One-way repeated ANOVA		
		Mean	SD	E-N significance	Mean	SD	E-N significance	Mean	SD	E-N significance	P	T1-T2	T1-T3
SNA (°)	Extraction	81.80	4.48	NS	79.93	3.80	NS	81.68	3.86	NS	0.76	-1.87	-0.13
	Non Extraction	81.58	4.09		80.39	3.36		80.33	3.80		0.19	-1.18	-1.24
SNB (°)	Extraction	78.00	4.18	NS	76.68	4.13	NS	77.99	3.96	NS	0.92	-1.33	-0.02
	Non Extraction	77.89	3.71		77.32	4.33		77.07	3.96		0.14	-0.58	-0.82
Facial angle (°)	Extraction	85.12	3.73	NS	86.20	3.97	NS	85.13	3.92	NS	0.33	1.08	0.01
	Non Extraction	85.52	3.42		86.13	3.40		86.28	3.81		0.93	0.60	0.75
Mandibular plane angle (°)	Extraction	31.50	4.82	NS	27.91	6.68	NS	31.34	5.09	NS	0.53	-3.60	-0.17
	Non Extraction	30.92	5.09		28.23	5.39		28.43	6.00		0.62	-2.69	-2.48
U1-FH (°)	Extraction	116.19	5.27	NS	113.78	7.89	*	111.68	7.17	*	0.00	-2.40 ††	-4.51 ††
	Non Extraction	114.57	7.41		116.98	5.91		116.74	5.82		0.09	2.41	2.17
L1-Mandibular plane (°)	Extraction	94.21	9.57	NS	92.89	6.81	*	89.78	8.86	*	0.00	-1.32 ††	-4.44 ††
	Non Extraction	90.28	8.99		96.06	5.92		95.71	5.58		0.03	5.77 †	5.42
U1-APO (mm)	Extraction	9.36	2.47	NS	7.65	2.23	**	7.44	2.00	*	0.00	-1.71 ††	-1.92 ††
	Non Extraction	7.72	1.91		9.37	1.65		9.48	1.76		0.00	1.65 ††	1.76 ††
L1-APO (mm)	Extraction	5.68	2.28	NS	4.20	2.91	**	3.84	1.87	**	0.00	-1.48 ††	-1.84 ††
	Non Extraction	4.03	2.06		5.91	1.82		5.90	1.67		0.01	1.88 †	1.88 †
Overbite (mm)	Extraction	2.71	1.55	NS	3.04	1.70	**	2.82	0.96	*	0.31	0.33	0.11
	Non Extraction	3.16	1.04		2.03	0.58		2.38	0.69		0.03	-1.14 †	-0.78
Overjet (mm)	Extraction	3.48	2.02	NS	3.36	1.49	NS	3.32	0.84	NS	0.78	-0.12	-0.16
	Non Extraction	3.56	0.98		3.42	0.90		3.26	0.97		0.91	-0.14	-0.30
U1-L1 to FH (°)	Extraction	43.21	7.70	NS	43.16	11.71	*	46.43	8.40	NS	0.07	-0.05	3.22
	Non Extraction	43.34	8.93		40.73	5.56		43.17	6.83		0.56	-2.62	-0.17
Condylar incial angle (°)	Extraction	85.47	8.66	NS	89.29	7.29	NS	90.85	6.99	NS	0.00	3.83 ††	5.38 ††
	Non Extraction	90.10	6.88		86.48	6.37		86.57	5.68		0.05	-3.61 †	-3.53

P*<.05 (Unpaired t-test); *P*<.01 (Unpaired t-test); †*P*<.05 (Dunnet t-test); ††*P*<.01 (Dunnet t-test).

Table 2. Cast model analysis.

Measurements	Extraction Group (n=21)		Nonextraction Group (n=10)		Significant
	Mean	SD	Mean	SD	
Maxillary Central incisor (mm)	8.98	0.49	8.37	0.47	**
Lateral incisor (mm)	7.49	0.49	6.92	0.77	**
Canine (mm)	8.30	0.38	7.89	0.25	***
1st premolar (mm)	7.70	0.55	7.18	0.36	**
2nd premolar (mm)	7.18	0.57	6.74	0.38	*
1st molar (mm)	10.76	0.57	10.18	0.54	**
2nd molar (mm)	10.62	0.54	9.68	0.70	**
Mandibular central incisor (mm)	5.74	0.36	5.27	0.37	**
Lateral incisor (mm)	6.37	0.39	5.90	0.30	*
Canine (mm)	7.14	0.31	6.76	0.17	**
1st premolar (mm)	7.67	0.48	7.17	0.32	*
2nd premolar (mm)	7.60	0.59	7.08	0.57	*
1st molar (mm)	11.80	0.64	11.05	0.72	*
2nd molar (mm)	11.21	0.79	10.27	0.85	***
Maxillary arch length discrepancy (mm)	-7.83	3.59	-1.97	2.99	***
Mandibular arch length discrepancy (mm)	-7.04	3.79	-2.58	2.60	**
Anterior ratio (%)	77.75	2.79	77.67	3.61	NS
Over all ratio (%)	91.90	2.70	91.60	2.76	NS
Irregularity index (mm)	8.52	4.40	3.10	1.60	***

NS indicates not significant.
P*<.05; *P*<.01; ****P*<.001 (Unpaired t-test).

cantly, from 7.72±1.91 mm at T1 to 9.37±1.65 mm at T2 (+1.65 mm, *P*<.01) and 9.48±1.76 mm at T3 (1.76 mm, *P*<.01). The mean values at T2 and T3 were significantly smaller in the extraction

group (T2 : 9.37±1.65 mm ; T3 : 9.48±1.76 mm ; *P*<.01 and *P*<.05, respectively).

Regarding the mandibular central incisors, in the extraction group, mean L1-mandibular

plane value decreased significantly, from $94.21 \pm 9.57^\circ$ at T1 to $92.89 \pm 6.81^\circ$ at T2 (-1.32° , $P < .01$) and $89.78 \pm 8.86^\circ$ at T3 (-4.44° , $P < .01$). In the nonextraction group, mean L1-mandibular plane value was $90.28 \pm 8.99^\circ$ at T1, $96.06 \pm 5.92^\circ$ at T2, and $95.71 \pm 5.58^\circ$ at T3. Although mean L1-mandibular plane value increased by 5.77° ($P < .05$) *between* T1 and T2, no significant difference was observed *between* T1 and T3 ($P > .05$). Mean L1-mandibular plane values at T2 and T3 were significantly larger in the nonextraction group (both $P < .01$).

Mean L1-APO value in the extraction group decreased significantly, from 5.68 ± 2.28 mm at T1 to 4.20 ± 2.91 mm at T2 (-1.48 mm, $P < .01$) and 3.84 ± 1.87 mm at T3 (-1.84 mm, $P < .01$). In the nonextraction group, mean L1-APO plane value increased significantly, from 4.03 ± 2.06 mm at T1 to 5.91 ± 1.82 mm at T2 ($+1.88$ mm, $P < .05$) and 5.90 ± 1.67 mm at T3 ($+1.88$ mm, $P < .05$). Mean L1-APO plane values at both T2 and T3 were significantly larger in the nonextraction group (both $P < .01$).

Regarding the association *between* the maxillary and mandibular central incisors, the extraction group exhibited no significant difference in overbite either *between* T1 and T2 or *between* T1 and T3. In the nonextraction group, overbite was 3.16 ± 1.04 mm at T1, which decreased significantly to 2.03 ± 0.58 mm at T2 (-1.14 mm, $P < .05$). However, overbite at T3 decreased by -0.78 mm, not significantly different from T1. Regarding overjet, no significant difference was revealed by any intragroup or intergroup comparisons.

Regarding the U1-L1 to FH plane, no significant difference was revealed by any intragroup comparison. At T2, the U1-L1 to FH plane value of the nonextraction group ($40.73 \pm 5.56^\circ$) was significantly smaller ($43.16 \pm 11.71^\circ$; $P < .05$).

Mean condylar incisor angle in the extraction group increased significantly, from $85.47 \pm 8.66^\circ$

at T1 to $89.29 \pm 7.29^\circ$ at T2 ($+3.83^\circ$, $P < .01$) and $90.85 \pm 6.99^\circ$ at T3 (5.38° , $P < .01$). In the nonextraction group, this angle was $90.10 \pm 6.88^\circ$ at T1, decreasing significantly to $86.48 \pm 6.37^\circ$ at T2 (-3.61° , $P < .05$). However, no significant difference in this angle was observed *between* T1 and T3 ($86.57 \pm 5.68^\circ$). Regarding the condylar incisor angle, no significant difference was observed *between* groups at any time point (T1, T2, or T3).

2. Cast Model Analysis

Table 2 shows the mean cast-model measurements of both groups. The mesiodistal coronal widths of all teeth were significantly larger in the extraction group ($P < .05$). Moreover, the maxillary and mandibular arch-length discrepancies were significantly greater ($P < .01$) in the extraction group. No meaningful differences in anterior or overall Bolton ratios were observed *between* groups. However, the irregularity index was significantly higher in the extraction group ($P < .001$).

DISCUSSION

Treatment of Class I crowding using a preadjusted appliance caused no skeletal changes, regardless of extraction/nonextraction status. However, there were intergroup differences in movements of maxillary and mandibular central incisors.

In the extraction group, U1-APO plane values revealed that maxillary central incisors moved 1.71 mm posteriorly at T2. At T1 and T3, the value was 1.92 mm posterior. U1-FH plane values showed that maxillary central incisors were slightly inclined lingually at T2. At T3, the value decreased further, and incisors became more lingually inclined. Cho *et al.*⁷⁾, who made three-dimensional measurements of Class I malocclusion with dental-cast models based on an MBT setup in patients undergoing extraction, reported that maxillary central incisors

were lingually inclined by an average of 12.30° and moved posteriorly by an average of 5.40 mm. Although it is not clear whether torque to the maxillary central incisors was 17° or 22° , mean arch-length discrepancy of the maxillary central incisors in that report was mild (2.55 ± 1.08 mm). Thus, closure of extraction space by sliding might have been significant, and the torque to the maxillary central incisors might have been lost. We also observed that maxillary central incisors were lingually inclined, and concluded that torque to maxillary central incisors should be larger than 17° in similar cases.

In the nonextraction group, U1-APO plane values revealed that maxillary central incisors moved anteriorly at T2 and then moved slightly anteriorly at T3. However, inclination of maxillary central incisors remained constant between T1 and T3. Thus, the torque of 17° built into the maxillary central incisor brackets was effective. Miyake *et al.*⁽⁹⁾, also discussed above, reported that although no change in inclination of the axes of maxillary and mandibular central incisors was observed in either group, maxillary central incisors moved 1.31 mm posteriorly in the extraction group and 1.43 mm anteriorly in the nonextraction group. Because the U1-FH plane value before treatment in the extraction group in Miyake *et al.*⁽⁹⁾ (111.77°) was smaller than our value (116.19°), their results might indicate a situation in which the axes of maxillary central incisors were inclined lingually and moved posteriorly after treatment.

Based on the L1-APO values, the mandibular central incisors moved 1.48 mm posteriorly at T2 and 1.84 mm posteriorly at T3 in the extraction group. In the nonextraction group, the mandibular central incisors moved 1.88 mm anteriorly at T2, and their positions were maintained at T3. Based on the L1-mandibular plane values, mandibular central incisors in the

extraction group, which had been labially inclined by 94.21° , were lingually inclined by 1.32° at T2 and further lingually inclined to 89.78° at T3, a good result. However, in the nonextraction group, mandibular central incisors, which had been inclined by 90.28° at T1, were labially inclined by 96.06° at T2 and remained so at T3. Pandis *et al.*^(10,11) reported that, after malocclusion in patients with an irregularity index of 2 mm or larger was treated with .022 self-ligation brackets (Damon2 or Damon3) without extraction, mandibular anterior teeth were inclined labially. Scott *et al.*⁽¹²⁾ confirmed such labial incline after treatment with Damon3 self-ligation brackets. Here, although the mandibular central incisor bracket had a built-in torque of -6° even in the MBT setup, the mandibular central incisors were labially inclined at T2 in the nonextraction group, consistent with those studies. Although there were intergroup differences regarding movement of maxillary and mandibular anterior teeth, U1-L1 to FH, an incisal guide angle similar to the anterior guidance angle that affects mandibular movement^(2-5,13), exhibited no significant difference between T1 and T3 in either group.

The occlusion function may contribute to mandibular anterior tooth crowding⁽¹⁴⁾, and should be examined in terms of anterior guidance. At T2, mean U1-L1 to FH plane value in the nonextraction group was 40.73° , significantly smaller than 43.16° in the extraction group ($P < .05$). Costa *et al.*⁽¹⁵⁾ reported that, based on measurement of 163 Caucasian skulls using cone-beam computed tomography (CBCT), the mean anterior guidance angle was 48.16° for both the right and left central incisors. In this study, the angle ranged from $43-46^\circ$ in the extraction group and $40-43^\circ$ in the nonextraction group. In both groups, the angle was around 43° , and it was assumed that this angle was maintained by treatment with a preadjusted

appliance. This supports the view of McHorris²⁻⁴⁾ that the anterior guidance angle is maintained constant by functional requirements. Although the absence of changes caused by treatment implies that occlusion movement functioned well in both groups, the anterior guidance angle was smaller than that reported by McHorris (47°).

Regarding changes in condylar incisal angle, the values in the extraction group were 89.29° at T2 and 90.85° at T3. These angles are close to 90°, at which function is regarded to be most stable³⁾. On the other hand, in the nonextraction group, this angle changed from 90.10° at T1 to 86.48° at T2 ; thus, mandibular central incisors became labially inclined ($P<.05$). Although no significant difference was observed, the angle at T3 was 86.57° and tended to approach the pre-treatment value. Therefore, because mandibular central incisors became labially inclined after treatment, a compensatory mechanism might have held the anterior guidance angle constant by reducing the condylar incisal angle.

Fleming *et al.*¹⁶⁾ report that postoperative occlusal conditions varied in patients receiving nonextraction treatment of Class I malocclusion. Bernabe *et al.*¹⁷⁾, who examined the severity of crowding and mesiodistal coronal width, reported greater mesiodistal coronal width in patients with crowding. Poosti and Jalali¹⁸⁾ state that mesiodistal coronal width is the primary cause of crowding.

In our nonextraction group, the arch-length discrepancy was -2.58 mm, and the irregularity index was 3.10 mm. Thus, in nonextraction treatment, inadequate available arch length or disagreement in size ratio *between* maxillary and mandibular teeth might have caused labial inclination of the mandibular central incisors after treatment.

Also in our nonextraction group, the anterior ratio was $77.67\pm3.61\%$, close to $77.2\pm1.65\%$,

the Bolton standard ; there were no significant intergroup differences. Endo *et al.*¹⁹⁾, who examined tooth-size ratios from male and female Japanese orthodontic patients, stated that anterior and overall ratios were $78.39\pm2.18\%$ and $91.60\pm2.11\%$, respectively, and that there was a significant difference *between* anterior ratio and the Bolton standard. In our nonextraction group, anterior ratio was almost identical to the Bolton standard. Thus, labial inclination of mandibular anterior teeth was not caused by size disagreement *between* maxillary and mandibular teeth, but possibly instead by irregularity index (3.10 mm).

Edman Tynelius *et al.*²⁰⁾ compared changes in retention capacity after 1 year among three retention methods : vacuum-formed retainer, stripping of mandibular anterior teeth, and positioner. Small but significant differences were observed *between* the retainer and stripping groups regarding mandibular canine width, mandibular arch length, and overbite. Thus, stripping of mandibular anterior teeth may favorably affect their positions during retention, increase available arch length, and prevent mandibular central incisors from becoming inclined labially.

Depending on extraction status, different strategic treatments are required for treatment of Class I crowding using a preadjusted appliance. Our results demonstrate that maxillary central incisors were lingually inclined at T2 in the extraction group. Thus, in extraction treatment, improvement in the inclination of maxillary central incisors and better occlusion *between* maxillary and mandibular anterior teeth can be achieved using brackets with a torque of +22°, 5° greater than the torque of +17° of the bracket prescription²¹⁾ for the maxillary central incisors we used.

Meanwhile, in nonextraction treatment, the appropriate prescriptions for maxillary and

mandibular central incisors are $+17^\circ$ and -6° , respectively. However, stripping the mesiodistal coronal widths of mandibular anterior teeth may increase available arch length and prevent mandibular central incisors from being inclined labially. Consequently, mandibular anterior teeth can be stabilized during retention.

Mandibular central incisor brackets have built-in torque of -6° . However, because the mandibular central incisors were revealed to be inclined labially, stripping may effectively resolve a mild irregularity index.

CONCLUSION

Treatment of Class I crowding using a preadjusted appliance ensures good occlusion after the retention period. However, different bracket prescriptions are required to align anterior teeth in cases of first premolar extraction or nonextraction, due to differences in anterior tooth movement that depend on extraction status.

ACKNOWLEDGMENTS

The author expresses sincere appreciation to the faculty of Ohu University School of Dentistry, whose cooperation greatly aided this study.

A summary of this report was presented at the 46th Meeting of the Ohu University Dental Society on November 8, 2008, in Koriyama, Japan.

REFERENCES

- 1) Thickett, E., Taylor, N. G. and Hodge, T. : Choosing a pre-adjusted orthodontic appliance prescription for anterior teeth. *J. Orthod.* **34** ; 95-100 2007.
- 2) McHorris, W. H. : Occlusion with particular emphasis on the functional and parafunctional role of anterior teeth. Part 1. *J. Clin. Orthod.* **13** ; 606-620 1979.
- 3) McHorris, W. H. : Occlusion with particular emphasis on the functional and parafunctional role of anterior teeth. Part 2. *J. Clin. Orthod.* **13** ; 684-701 1979.
- 4) McHorris, W. H. : Focus on anterior guidance, Introduction. *J. Gnathol.* **8** ; 3-13 1979.
- 5) Hobo, S. and Takayama, H. : A new system for measuring condylar path and computing anterior guidance : Part I. Measuring principle. *Int. J. Prosthodont.* **1** ; 99-106 1988.
- 6) Miyake, H., Ryu, T. and Himuro, T. : Effects on the dental arch form using a preadjusted appliance with premolar extraction in Class I crowding. *Angle Orthod.* **78** ; 1043-1049 2008.
- 7) Cho, M. Y., Choi, J. H., Lee, S. P. and Baek, S. H. : Three-dimensional analysis of the tooth movement and arch dimension changes in Class I malocclusions treated with first premolar extractions : A guideline for virtual treatment planning. *Am. J. Orthod. Dentofacial Orthop.* **138** ; 747-757 2010.
- 8) Little, R. M. : The irregularity index : a quantitative score of mandibular anterior alignment. *Am. J. Orthod.* **68** ; 554-563 1975.
- 9) Bolton, W. A. : Disharmony in tooth size and its relation to the analysis and treatment of malocclusion. *Angle Orthod.* **28** ; 113-130 1958.
- 10) Pandis, N., Polychronopoulou, A., Makou, M. and Eliades, T. : Mandibular dental arch changes associated with treatment of crowding using self-ligating and conventional brackets. *Eur. J. Orthod.* **32** ; 248-253 2010.
- 11) Pandis, N., Polychronopoulou, A. and Eliades, T. : Self-ligating vs conventional brackets in the treatment of mandibular crowding : A prospective clinical trial of treatment duration and dental effects. *Am. J. Orthod. Dentofacial Orthop.* **132** ; 208-215 2007.
- 12) Scott, P., DiBiase, A. T., Sherriff, M. and Courbourn, M. T. : Alignment efficiency of Damon3 self-ligating and conventional orthodontic bracket systems : A randomized clinical trial. *Am. J. Orthod. Dentofacial Orthop.* **134** ; 470.e1-470.e8 2008.
- 13) Abboud, M., Grüner, M. and Koeck, B. : Anterior crowding--just an esthetic problem? *J. Orofac. Orthop. / Fortschr. Kieferorthop.* **63** ; 264-273 2002.
- 14) Shigenobu, N., Hisano, M., Shima, S., Matsubara, N. and Soma, K. : Patterns of dental crowding in the lower arch and contributing factors. *Angle Orthod.* **77** ; 303-310 2007.
- 15) Costa, H. N., Slavicek, R. and Sato, S. : A three-dimensional computerized tomography study into the morphological interrelationship between anterior and posterior guidance and

- the occlusal scheme in human Caucasian skulls. *J. Stomat. Occ. Med.* 4 ; 10-19 2011.
- 16) Fleming, J. W., Buschang, P. H., Kim, K. B. and Oliver, D. R. : Posttreatment occlusal variability among angle Class I nonextraction patients. *Angle Orthod.* 78 ; 625-630 2008.
- 17) Bernabé, E. and Flores-Mir, C. : Dental morphology and crowding : A multivariate approach. *Angle Orthod.* 76 ; 20-25 2006.
- 18) Poosti, M. and Jalali, T. : Tooth size and arch dimension in uncrowded versus crowded Class I malocclusions. *J. Contemp. Dent. Pract.* 8 ; 45-52 2007.
- 19) Endo, T., Shundo, I., Abe, R., Ishida, K., Yoshino, S. and Shimooka, S. : Applicability of Bolton's tooth size ratios to a Japanese orthodontic population. 95 ; 57-60 2007.
- 20) Edman, G., Bondemark, L. and Lilja-Karlander, E. : Evaluation of orthodontic treatment after 1 year of retention--A randomized controlled trial. *Eur. J. Orthod.* 32 ; 542-547 2010.
- 21) Farronato, G., Periti, G., Giannini, L., Farronato, D. and Maspero, C. : Straight-wire appliances : Standard versus individual prescription. *Prog. Orthod.* 10 ; 58-71 2009.
- 著者への連絡先 : 竜 立雄, (〒963-8611)郡山市富田町字三角堂31-1 奥羽大学歯学部成長発育歯学講座歯科矯正学分野
Reprint requests : Tatsuo RYU, Division of Orthodontics and Dentofacial Orthopedics, Department of Oral Growth and Development, Ohu University School of Dentistry
31-1 Misumido, Tomita, Koriyama, 963-8611, Japan